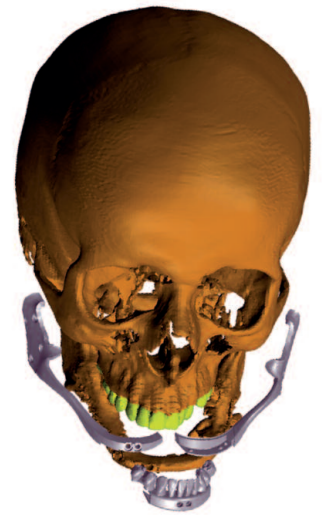

Mandibular body reconstruction with a 3-D printed implant



Authors _Dr Saeid Kazemi, Reza Kazemi, Sita Rami Reddy Jonnala & Dr Ramin S. Khanjani, Sweden

_Nowadays, no aspect of human life seems to have been left untouched by the ever-expanding digital technology. Particularly in scientific fields, digitalisation has working wonders during the past few years, to the degree that it is even difficult to imagine going back to the ordeal of analogue methods and putting up with their vagaries. A remarkable blessing of digital technology, among others, is the exceptional precision and high control over the measurements, never possible to obtain through any of the preceding methods. There is no surprise then that it has the strongest appeal to the fields of knowledge and practice wherein precision is amongst the most critical element of success.

_Hot spot for digital technology

With a lot of technical sensitivity at its heart, the dentistry can easily be viewed as a hot spot for implementing digital technology to achieve the most-wished precision. Indeed, the digital technology has already gained a stable foothold in dentistry and there is an ongoing shift towards embracing digital systems into the dental practice. Predictably, the majority of the advertised technologies and services are geared towards routine dental procedures. On the other hand, the most significant advancements have been wit-

nessed in an area which falls only within the experience of specialists; it is the domain of maxillofacial surgery where tailoring the treatment plan to the unique conditions of the patient is the key to success. Here the state-of-art digital technology comes in handy to fully customise the treatment by taking the slightest details into consideration and reflecting that into the surgical and restorative solutions.

Though the successful reconstruction of any human structure is justifiably a challenge, the stakes are even higher when the oral and maxillofacial area is affected. In this latter case, care must be taken to retrieve function in conjunction with restoring aesthetics. Oftentimes, even the second objective might take precedence. As such, the significance of precision and adaptability to the existing structures for the maxillofacial implants cannot be overemphasised. Fortunately, with the advent of 3-D digital designing and additive manufacturing a fully satisfactory treatment is no more a remote possibility.

The virtual environment of 3-D software accommodates full inspection of the surgical area from multiple angles. It also facilitates designing and adjustment of the form of the future implant with much ease and with respect to topography of the surrounding structures. Thanks to the available technology and material, now it is possible to 3-D print such intricate designs with above-standard accuracy and minimum technical glitch. The result is the highest fit of precision always craved for by maxillofacial surgeons to complement their skilful incisions.

_Case presentation

Since its inception, DRSK Company has been committed to explore potentials for incorporation of the digital and computer science into the dental field by

Fig. 1 _One-of-a-kind mandibular implant as reconstruction for the missing mandible body.

Fig. 2 _Replica of the patient's skeleton. Missing mandible body replaced with a fibula graft.



Fig. 1

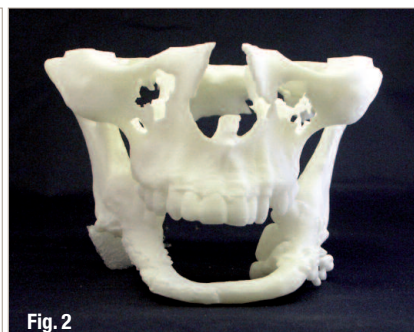


Fig. 2

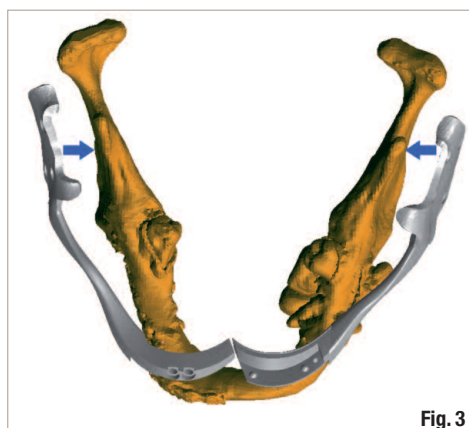


Fig. 3

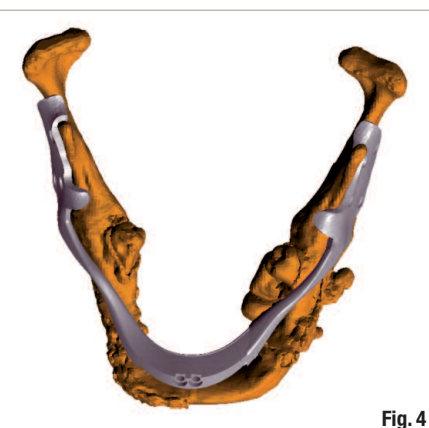


Fig. 4

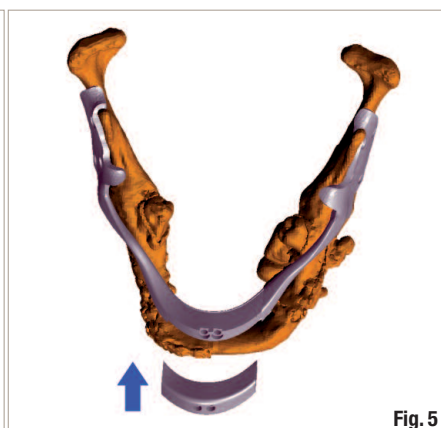


Fig. 5

devising innovative solutions. With 3-D services being a major activity of DRSK, the company has been approached for 3-D designing the maxillofacial implants of different kinds and successfully accomplished them. All these 3-D designed implants are highly customised and feature great accuracy and therefore satisfy both surgical and mechanical standards.

Patient case

One such recently carried out project that merits further elaboration is the design and manufacture of one-of-a-kind mandibular implant (Fig. 1) for recon-

structing the missing mandible body (Fig. 2). The patient, a young man, had lost the entire mandible except for the rami after being severely injured in a blast. Over the years, the patient had undergone several surgeries with little improvements achieved. In point of fact, one consequence of those surgeries was the formation of fibrous scar tissues which, as will be explained in the following, exacerbated the situation and restricted the chance for an effective treatment.

At the time the surgical team contacted DRSK, the patient had already received a graft taken from his


Fig. 3 Left and right segments of the implant were designed to be placed and screwed over the corresponding ramus.

Fig. 4 At the front, left and right segments of the implant met and dovetailed into each other.

Fig. 5 A temporary or surgical middle piece was designed to be placed over the left and right sections at the surgical session.

AD

RatioPlant®
dental implant systems - the advanced way to care!



Distributors are welcome, please contact us under the address below:



Made in Germany

www.humantech-solutions.de

HumanTech Germany GmbH
Gewerbestr. 5
D-71144 Steinenbronn, Germany
email: sales@humantech-solutions.de
phone: +49.7157.5246.71

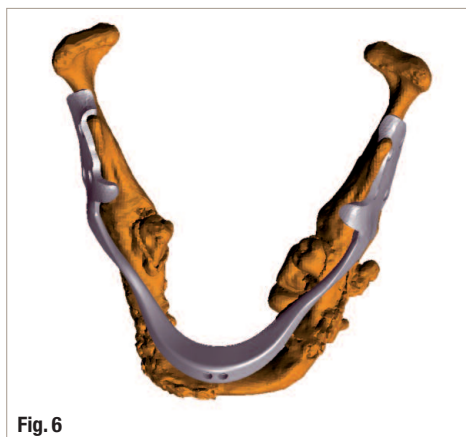


Fig. 6

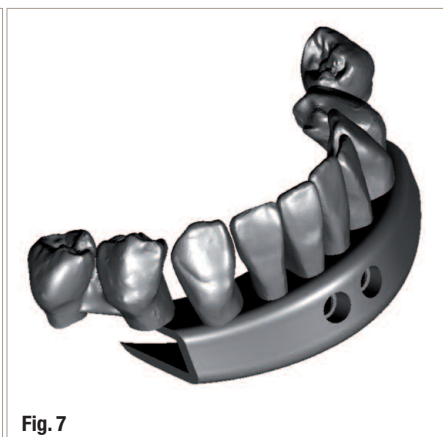


Fig. 7

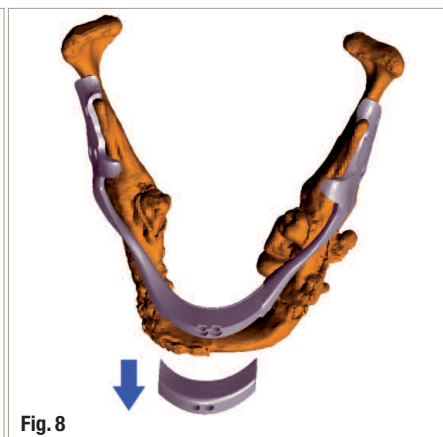


Fig. 8

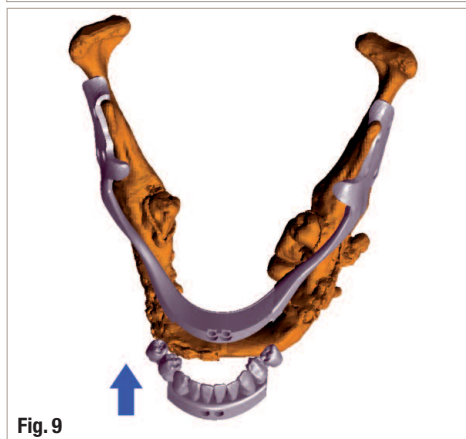


Fig. 9

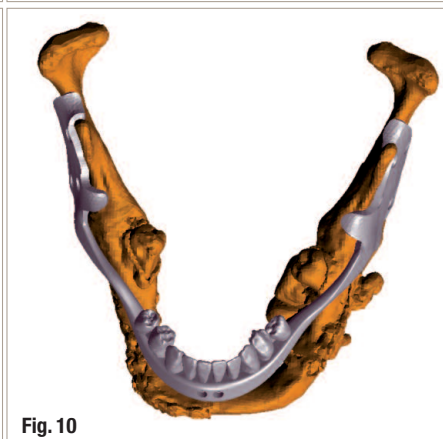


Fig. 10

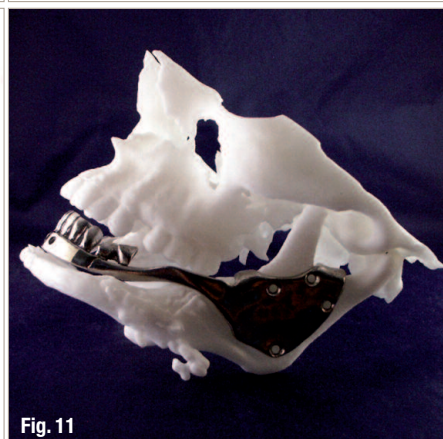

Fig. 11

Fig. 6_The middle piece should hold two pieces in place at the front.

Fig. 7_The prosthetic, permanent middle section.

Fig. 8_After the healing period: Insertion of the prosthetic component with unscrewing and removing of the surgical middle part.

Fig. 9_Insertion of the prosthetic middle section, carrying the teeth.

Fig. 10_Fixation of the prosthetic middle section.

Fig. 11_Final prosthesis shown over the patient's model.

fibula. Owing to the extent of structure loss, the graft alone failed to yield the anticipated results. Needless to say, the ultimate goal of the treatment was to improve the aesthetics and retrieve the function of the reconstructed jaw by a prosthetic treatment and giving the patient a chance to experience an almost normal mastication once more. However, the form and size of the grafted bone could not provide the required support for prosthetic structures such as dental fixtures.

Eventually, the surgical team decided to seek assistance from DRSK and use its 3-D services expertise to design and manufacture an ad hoc mandibular implant that fully complies with the patient's unfavourable conditions and enables the complementary prosthodontics treatment. The overall shape of the implant and its relation with other anatomic structures, including the grafted bone and the soft tissue were all fleshed out and requested by the surgical team. One stipulation of the surgical team was to keep the previously grafted fibula. They considered it as a safety measure in event of implant's failure.

The design solution

One big challenge to carry out this particular project was to design the implant in such a way that it can be easily seated in the correct position. There were two major impediments to a one-piece implant solu-

tion. First of all, the implant was intended to be mounted over the remaining parts of the patient's jaw, i.e. his two rami. To achieve the maximum anchorage from the rami, those parts of the implant connecting them were supposed to adapt to their external anatomy. Since the rami converge to the front, the same was expected from the corresponding implant design.

However, such designing choice would have made the matters complicated for surgical placement of the implant. What's more, the fibrous tissues resulting from the previous surgeries have dramatically reduced the patient's ability to open his mouth. Therefore, DRSK 3-D design team had to cross out the one-piece implant solution. Eventually by taking different limitations into account and after consulting with the surgical team and receiving their endorsement, it was decided to make the prosthesis in three pieces.

Each of the two larger left and right segments of the implant was designed to be placed and screwed individually over the corresponding ramus (Fig. 3), while at the front they met and dovetailed into each other (Fig. 4). A third part then had to be placed over the two pieces at their interface, embrace both and hold them together securely (Figs. 5 & 6). This way the whole thing turned into a unified structure.

Excellent fit with 3-D designing

The success of the proposed design was to a large extent reliant on obtaining an excellent fit for each piece. This is the reason why the role of 3-D design and manufacture was so essential in this procedure. The parts of the right and left sections that meet the rami had to be exactly adapted to the form of their corresponding anatomic structures. Each of them had to be formed in such a way that can fold over the edges of the ramus and embrace it enough for a proper support. Using 3-D design as well guaranteed the perfect contacts between three pieces which otherwise might have been an area of concern for a design of this nature.

Given the necessity for including a prosthetic solution and considering the patient's limited mouth opening, the most feasible solution was to incorporate the artificial teeth into the structure of the mandibular implant. As described above, during the surgical procedure and after screwing left and right pieces over the rami, the two overlapping front ends of left and right parts were fully fixed in place by adding the middle segment. The idea for the final design was to include the artificial teeth as part of this middle section.

However to eliminate the risk of any force or pressure that would have compromised the success of the surgery, a temporary or surgical middle piece was designed to be placed over the left and right section at the surgical session (Fig. 5). The function of this piece was simply to hold two pieces in place at the front (Fig. 6) before being replaced with the prosthetic, permanent middle sections (Fig. 7).

The prosthodontic component

On the surgical team's recommendation, the mandibular dentition included in the design of the middle section only comprised ten teeth including incisors, canines and premolars on both sides (Fig. 7). Due to the size of third surgical piece and its function of uniting the other two sections, only incisors and canines are in contact with the interconnecting surface of the middle part. So when the middle prosthetic piece is seen independently, the premolars look unsupported in the manner of a cantilever bridge.

However, after insertion of this enfolding middle part over the overlapped arms of left and right pieces, the premolars become tightly in contact with left and right sections; this prevents any destructive lever function from taking place. Again such close contact has only been enabled by the accuracy of 3-D designing and the following 3-D print procedure.

The particular design of arms of left and right pieces, which collectively form the body of the mandible, is also worthy of note. These arms feature a

90 degree twist in the approximate area of molars. In this way they can adopt to both the thinner posterior part which is anchored over the ramus and the frontal part that required a broader width for carrying the teeth. Such twist also offered a solution for the relative lack of space in the posterior part of the mouth. This curve can as well bolster the physical resistance of the mandibular implant to the mechanical pressures.

3-D printing

As the designing procedure finished, the designed implant had to be manufactured and delivered to the surgical team. All three pieces were 3-D printed in Titanium Grade 5 using EBM technology. Also before installing the implant, patient's facial skeleton needed to be reproduced in a plastic material. It was 3-D printed by means of SLS technology. This replica was produced in order to give the surgeon a better idea of the surgical site and therefore facilitate the surgical process.

After the healing period, the time comes for insertion of the prosthetic component. At this stage the surgical middle part will be unscrewed and removed (Fig. 8) and the prosthetic middle section, carrying the teeth, will be inserted (Fig. 9) and fixed in place (Fig. 10 & 11). After checking the occlusion the patient's bite is to be registered. The sizes of the teeth have to be adjusted accordingly. As the next step, a layer of porcelain should be added to the teeth to finalise the prosthetic phase and thereby the treatment process.

Summary

In brief, the 3-D design has paved the way for devising unorthodox, novel surgical and prosthodontics solutions, as exemplified by the case presented in this article. Such alternative solutions could not be achieved through traditional technology with the same level of accuracy, which is essential for achieving the desired outcome.

The 3-D designing and 3-D printing therefore have infinitely widened the scope of maxillofacial surgeries by expanding and improving the potentials for customisation. Hence, it is now of utmost importance for maxillofacial surgeons to get further familiar with areas of application of these empowering tools and learn about opportunities for enlisting its assistance.

contact

Dr Saeid Kazemi

DRSK Group AB
Kasernvagen 2, SE-281 35
Hassleholm, Sweden
Tel.: +46 705 129909
www.drsk.com